

# Clinic News

## Palmer Clinics Case Report Epilepsy - Team Approach Proves Successful

by John S. Mosby, Jr., D.C., M.D. and  
Nils Heubach, Editor

On July 16, 1989, Dr. Hess, Director of Palmer Clinics, received a phone call from distraught parents asking for help with their severely epileptic five year old daughter. After intensive medical treatment of about ten months, they had just received a poor prognosis from Mayo Clinic. Previous chiropractic care had shown no results and the little girl was suffering up to thirty seizures a day with no seizure free days, was wearing a protective helmet and demonstrated severe attention deficit.

As with all difficult cases and referrals handled by Palmer Clinics, a specialized team of clinicians was immediately called into action. Experienced chiropractors from both the Clinic Department and the Department of Diagnosis were called in on

this case and Dr. Chris Hendricks was put in charge of the team. The team consisted of Drs. Hendricks, Mosby and Hagen and Larkin.

Drawing from their individual areas of expertise, the team doctors each contributed to the quality of the assessment made. Dr. Hendricks, with her background in pediatrics, made an extensive review of the child's health history from medical records supplied by the parents. Dr. Larkin reviewed past physical examination findings, while Dr. Mosby, who along with his D.C. degree also holds an M.D., reviewed all past medications related to the epileptic treatment and performed a detailed musculoskeletal examination. Dr. Hagen's well rounded background in different techniques and vast clinical exper-

ence added depth to the chiropractic assessment.

All team members placed high significance on the fact that the girl had suffered an injury to the head two hours prior to her first grand mal seizure. Static and motion palpation confirmed the suspicion of an upper cervical problem, after which Dr. Vern Hagen and student extern Bobby Goodman worked together and performed a specific upper cervical X-ray analysis.

Several upper cervical adjustments were performed at Palmer Clinics. The patient was then referred to a practitioner near her home who took care of her supported by recommendations from the Palmer Clinic team. Within 27 days of chiropractic care the seizures had abated. Since then the patient has exper-

enced occasional minor seizures only.

On a surprise visit to Palmer Clinics in March 1990, the team was delighted to see an alert and healthy little girl walk in unassisted and wearing no helmet!

**Advantages of the Team Approach**  
Palmer Clinics are in the fortunate position of having an extensive diversity of staff with a broad base of knowledge and expertise. Different teams are formed for different types of cases to enhance the quality of care.

Referring a difficult case to Palmer for evaluation and treatment can be advantageous since the patients are returned to the field practitioner with specific recommendations.

This case has been published in the Chiropractic Journal. Please read the reprint on the following page.

# CESSATION OF A SEIZURE DISORDER: Correction of the Atlas Subluxation Complex

Robert J. Goodman, D.C., John S. Mosby Jr., D.C., M.D.

## ABSTRACT

Observations of one patient presenting with a seizure disorder are reported. Relief of symptoms is noted subsequent to correction of the misalignment of the occipito-atlanto-axial complex. The authors suggest a

relationship between the misaligned skull and sub-  
cent vertebral and some seizure disorders.  
Key Words: epilepsy; atlanto-occipital joint

## INTRODUCTION

The term epilepsy refers to any disorder characterized by recurrent seizures. Seizures are transient disturbances of cerebral function due to abnormal paroxysmal neuronal discharges in the brain. Approximately 0.5% of the U.S. population is affected.<sup>1,2</sup>

Epilepsy is grouped into two different etiological categories, idiopathic or constitutional and symptomatic epilepsy. In idiopathic or constitutional epilepsy, seizures usually begin between 5 and 20 years of age. No specific cause can be identified, and there are no other neurological abnormalities.<sup>1</sup> The causes of symptomatic epilepsy include abnormalities and perinatal injuries, disorders of metabolism, trauma, space-occupying lesions, vascular problems, degenerative disorders, and infectious diseases.<sup>1,3,4</sup>

Clinically, seizures are categorized by description. The two major descriptive classifications are partial seizures and generalized seizures. Partial seizures are determined by clinical observation and by electroencephalograph manifestations. They affect only a restricted part of one cerebral hemisphere. In simple partial seizures the patient remains conscious, but in complex partial seizures consciousness is lost. Partial seizures may evolve into generalized seizures.<sup>1</sup> Generalized seizures are categorized as petit mal or absence seizures, atypical seizures, myoclonic seizures, atonic seizures or tonic seizures, and tonic seizures, atonic seizures or tonic seizures, and tonic seizures that will not fit into any other category.

All doctors must be aware of a condition called status epilepticus which is the rapid succession of seizures so that the next seizure begins before the previous one has ended. Status epilepticus is a medical emergency since continuous epileptic activity can damage the brain permanently. Of course death may occur during a seizure if the patient aspirates contents of the stomach which either occlude airways or prevent adequate oxygenation.<sup>5</sup>

When patients have been seizure free for at least four years withdrawal of medication may be considered. There is unfortunately no way of predicting which patients can be managed without treatment. Recurrence of attacks is most likely in patients who initially fail to respond to therapy, those with convulsive jerking movements, those with multiple types, and those with continuing EEG abnormalities.<sup>1</sup>

## HISTORY

Patient E is a five year old white female, who was small at birth and born breech. During her first three years of life she had many viral infections and repeated attacks of otitis media. Some concern was expressed by her mother over growth and language retardation. At age 13 months, however, psychomotor skills had been assessed as normal.

At the age of 4 years 8 months, in October 1988, Patient E was playing at a day care center, when she struck her head on the underside of a table. Within two hours her first grand mal seizure occurred. Patient E's second seizure occurred within three weeks.

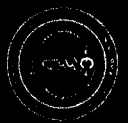bending; right leg deficiency of 3/4th to 1 inch; suspected cervical misalignment resulting in an atlas subluxation complex.

A specific upper cervical x-ray series was taken. During patient placement for the nasium view, certain postural deviations were noted. When asked to sit up straight, Patient E's head, cervical, and upper thoracic spine would not center directly over the pelvis and demonstrated excursion into the frontal plane. No pathologies were noted on the x-rays.

Chiropractic x-ray analysis revealed a misalignment of the occipito-atlanto-axial region. Figure 2 is a representation of a radiograph showing Patient E's misalignment in the frontal plane view. Rotation of atlas in the transverse plane was also measured, but was minimal.

# CHIROPRACTIC

The Journal of Chiropractic Research and Clinical Investigation



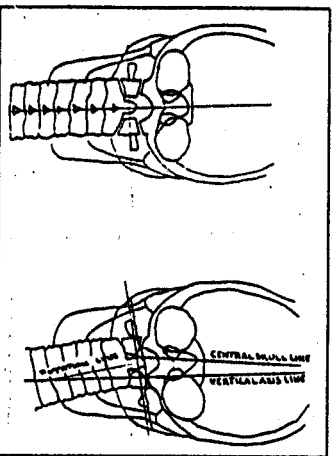
CHIROPRACTIC: The Journal of Chiropractic Research and Clinical Investigation  
Volume 6 - Number 2 - July 1990  
CESSATION OF SEIZURE DISORDER - GOODMAN

At the time of this report, the dosage had been reduced by almost one half for the past two weeks. Patient E has had six or fewer seizures per day. The seizures are completely absent on some days. After fewer than 60 days of chiropractic care Patient E has been speaking with five or six word sentences. A current speech evaluation is pending from her therapist and our patient has not been adjusted since July 1989. At re-evaluation, Patient E had no leg deficiency and her condition continues to improve.

## DISCUSSION

The authors could find little chiropractic literature pertaining to epilepsy or seizure disorders. Young reported on three cases which responded to chiropractic care.<sup>6</sup> In the medical articles reviewed on this subject, little hope, if any, is expressed for the control or cessation of childhood seizures of this type. Using statements like "woofally", "poor diagnosis", "refractoriness to treatment", "franght with uniform disappointment", and "grim foreboding",<sup>7</sup> this literature demonstrates the need for research not only in alternative methods of treatment, but also research into possible causative factors as well.

The remission of Patient E's epilepsy is a phenomenon whose timing is shortly preceded by the adjustment procedure. Perhaps not all seizure disorders can be helped with spinal adjustments. However, chiropractic care would surely be the most conservative treatment in the primary care system. Careful investigation into each case may reveal possible avenues that may eventually help the patient reduce or in some cases entirely eliminate the need for drug therapy.



a ↑

b ↑

c ↑

d ↑

a

b

c

d

Absence or petit mal seizures cause some reduction in postural tone, with some clonic or tonic components. Consciousness is impaired. These attacks occur quickly. When the attack occurs as a person is speaking, the person may miss a few words in mid-sentence then resume with the remainder of the sentence when the attack subsides. If a child has a petit mal seizure while playing for instance, he or she may freeze, that is, stand perfectly still while reaching for a toy. These seizures will often cease at approximately 20 years of age. Diagnosis is assisted by electroencephalographic studies which show bilateral synchronous and symmetric 3 Hz spike-and-wave activity.<sup>1</sup>

Atypical seizures are almost identical to the petit mal seizure except that changes in tone are more dramatic and onset and termination of the attack is slower.<sup>1</sup>

Myoclonic seizures cause single or multiple myoclonic jerks and myoclonic spikes are seen on an EEG.<sup>1</sup> Akinetic seizures present as a sudden loss of consciousness and EEG findings show synchronous firing from deep lesions often in the frontal regions of the brain.<sup>2</sup>

The grand-mal or tonic-clonic seizure occurs with a sudden loss of consciousness, the patient becomes rigid then falls to the ground and respiration is arrested for less than 60 seconds. This is described as the tonic phase. The next phase is the clonic phase during which the body jerks violently for 2 to 3 minutes. Flaccid coma occurs next. During this type of seizure the tongue may be bitten and urinary or fecal continence may be lost. The patient will then either recover consciousness, drift into sleep, or never recover consciousness, drift into sleep, or never recover consciousness which is called status epilepticus.<sup>1</sup>

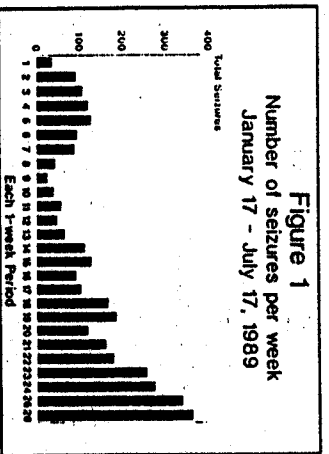
Atonic seizures are epileptic drop attacks where the patient, usually a child, loses all motor tone and falls to the ground.<sup>3</sup> The stigma of the helmet is often conferred of necessity on the patient with drop attacks in order to protect him from further injury during these attacks. These spells are often intractable to treatment. Finally, the onset of focal falling almost always occurs in patients who already have one or more other types of seizures and implies a poor prognosis for the ultimate seizure control and for normal mental development.<sup>3</sup>

Lennox-Gestaut Syndrome (L-G) is another classification of seizure disorder which has a peak age of onset of four years.<sup>4</sup> It is characterized by myoclonic and atypical absence seizures, regression of intellectual functions and generalized spike wave discharges on the EEG; at a rate below what is seen in petit mal seizures. Several hundred attacks may occur in a day and multiple injuries from falls are common. Diffuse cerebral atrophy is seen in 60% of cases.<sup>5</sup>

**MEDICAL TREATMENT**

The descriptive classifications above are important for determining the most appropriate medical treatment. When patients have recurrent seizures, medication is prescribed until there have been no seizures for at least four years. Epileptic patients are advised to avoid situations that could be dangerous or life-threatening during seizures.<sup>1</sup>

Patient E was evaluated at the Mayo Clinic and was experiencing 10 to 30 seizures per day with no seizure-free days. (Figure 1 is a graph prepared from Patient E's daily seizure journal kept by her parents. They recorded the number, time, type, and severity of each seizure.) Seizure types were described as being tonic, clonic, atonic, and grand mal. The diagnosis of Lennox-Gestaut Syndrome was made. The patient was described as being able to speak only a few intelligible phrases. She was tremulous, and had difficulty standing.



**Figure 1**  
Number of seizures per week  
January 17 - July 17, 1989

Various laboratory tests were performed including a complete blood count, serum ammonia, a CT scan and MRI were negative for fractures and pathologies. The EEG, however, showed a slow spike-wave abnormality as well as other features which may occur in Lennox-Gestaut syndrome. The prognosis was determined to be grave and the comment was made that the L-G syndrome is fraught with nearly uniform disappointing results since medical therapy has very few beneficial results.

Patient E was given Depakote, Zantone, and ACTH therapy. Each was given singly and then discontinued due to Patient E's unusual or aggressive behavior. Finally, Tegretol/carbamazepine seemed to have some positive effects on the grand mal type seizures. It was after this, however, that Patient E began to have drop attacks.

On July 18, 1989 Patient E entered into a team evaluation and treatment plan at the Palmer Chiropractic Clinic. At that time, Patient E was having 30 to 70 seizures per day. (Figure 1) Patient E presented with a helmet, face plate, and harness for protection against falls.

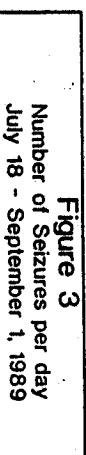The patient's communication skills were retarded. Physician exam revealed a waxy buildup in the ears so that the TM could not be visualized. Neurological exam revealed the presence of hyperreflexive and asymmetric reflexes. Orthopedic evaluation was unremarkable.

Further chiropractic evaluation revealed paravertebral muscular spasm in the cervical area, cervical ROM severely restricted especially in right lateral

To correct the subluxation, Patient E was placed on the adjustment table side posture with the C1 transverse process as the contact point. An adjusting force was introduced to the spine using specific upper cervical adjusting procedures.<sup>6</sup> The success of the adjustment was measured by lessening of leg disparity, increase of pelvic resistance, postural changes, and finally post adjustment x-ray analysis.

Patient E was adjusted on three consecutive days. After the first adjustment, Patient E's right leg changed from one inch deficiency to no noted deficiency.<sup>6</sup> The adjustment. The seizure pattern remained quiet after high that day. On the second day, the pre-adjustment leg deficiency was 1/4th inch on the right. After the adjustment, the legs were even and the pelvic resistance on the right was stronger than the day before. The adjustments were always made between 9:00 a.m. and 1:00 p.m. After 1:00 p.m. on the second day, Patient E had no more seizures during the day. On the third and final day of care at the Palmer Chiropractic Clinic the leg deficiency was 1/8th inch. Again, after the adjustment, the legs were even, and the pelvic resistance equal bilaterally. Patient E had no further seizures after 1:00 p.m. on this day. The parents of Patient E commented that she was showing more energy and stability when standing. A postural change was quite evident when Patient E was prepared for the post x-ray series. When instructed to sit up straight, Patient E's head and upper spine were centered over her pelvis. The vertical centering lines on the back were used for comparison. Post x-ray analysis revealed a 91% reduction of the misalignment factors with all structures centered on the vertical axis.

The parents had been counseled that after an adjustment they could expect exacerbations or changes in symptomatology on the 3rd, 7th, 14th and 28th day.<sup>7</sup> On the 17th day after the adjustment procedure, the seizures numbered almost 100 (more than ever before). On the 27th day the seizures abated. (Figure 3) The seizures remained absent for approximately four weeks. The carbamazepine dosage was not changed during this period.



**Figure 3**  
Number of Seizures per day  
July 18 - September 1, 1989

**ACKNOWLEDGMENTS**

The authors wish to acknowledge George Hess, D.C., Chris L. Hendricks, D.C., Vern Hagen, D.C., and Dale Stram, D.C. for their part in the care of Patient E and Alana Ferguson, M.S., Susan Larkin, D.C. and David Guerrero for help in manuscript preparation.

**REFERENCES**

1. Shorrock SA, Kripp MA, Tierney LM. Current medical diagnosis and treatment. Norwalk, CT: Appleton & Lange; 1986: 576-580.
2. Swadlow OC III. Epilepsy in children: a practical approach. Seminars in Neurology 1986; 6(1):24-34.
3. Allen RB. Nutritional aspects of epilepsy. International Clinical Nutrition Review 1983; 3(2): 3-10.
4. Recent advances in childhood epilepsy. 17th International Epilepsy Congress. Epilepsia 1986; 29 Supplement 3:51-524.
5. Sun JY. An analysis of the causes of epilepsy in 440 cases. Chung Hua Shen Ching Ching Shen Ko Tsa Chih 1968 June; 21(3):141-4.
6. Crowell CE, Bush B. Es. Pyridoxine-dependent seizures. Ann Fam Physician 1983; 2(3): 183-187.
7. Harry AM, Johns RJ, McKusick VA, Owens AH, Ross BS. Principles and practice of medicine. Norwalk, CT: Appleton-Century-Cook; 1984: 1234.
8. Anderson TC, Carpenter CCL, Pina F, Smith UJJ. Cerebral secretions of acetone. J Natl Philadelph Soc 1990; 190.
9. Evans OB, Hanson BE, Swadlow OC. The primary generalized epilepsies of childhood. Semin Neurol 1988 Spring; 8(1):12-21.
10. Prazgala P et al. Drop attacks: an ominous change in the evolution of partial epilepsy. Neurology 1986; 36: 1725-30.
11. Marland ON. Slow spike-wave activity in EEG and the associated clinical features: often called Lennox-Gestaut Syndrome. Neurology (Dallas) 1977; 27: 746-757.
12. Lauber J, Richens A, Ostry J (eds). Textbook of epilepsy. 3rd ed. New York: Churchill Livingstone; 1988.
13. Gregory RE. NUCCA basic course x-ray analysis. Moore, M. National Upper Cervical Chiropractic Association, Inc. 1986. Cervical Monograph 1986; 28(2):27.
14. Gregory RE. The NUCCA course: adjusting the atlas subluxation complex. Moore, M. National Upper Cervical Chiropractic Association, Inc. 1988.
15. Gregory RE. Biomechanics of C1 subluxation production. Upper Cervical Monograph 1986; 4(9).
16. Gregory RE. Post-adjustment healing cycle: nerve and tissue repair. NUCCA Educational Conference, May 1979; unpublished seminar notes.
17. Young C. Chiropractic success in epileptic conditions. ACA Journal of Chiropractic 1982; 19(4):62-63.

(Dr. Robert Goodman is in private practice in California. Dr. John Mosby is an assistant professor in the Department of Clinics of Palmer College of Chiropractic. Correspondence and requests for reprints should be addressed to Dr. Goodman at P.O. Box 15156, Newport Beach, CA 92660.)